

RESEARCH

Open Access



# Different methods of determining centric relation – comparison with a digital mandibular motion analyser

Bálint Jász<sup>1\*</sup>, Szilvia Ambrus<sup>1</sup>, Tamás Garay<sup>2,3</sup>, Péter Schmidt<sup>1</sup>, Péter Hermann<sup>1</sup>, Szandra Körmendi<sup>1</sup> and Máté Jász<sup>1</sup>

## Abstract

**Background** Finding and registering the maxillary–mandibular jaw relation is crucial in dental practice. Several comparative studies have been conducted to investigate the reproducibility and accuracy of techniques for determining the centric relation (CR) position of the mandible. The aim of our study was to determine which of seven different CR determination methods had the smallest deviation from the theoretical zero with the help of a digital mandibular motion analyser. The chosen theoretical zero position, the maximal intercuspal position (MIP), is the most reproducible and widely used position.

**Methods** Thirty-four volunteers (24 females and 10 males) with a mean (SD) age of 29.1 ( $\pm$  7.3) years with a negative history of temporomandibular disorder (TMD) participated in the study. A digital mandibular motion analyser was used to register the condylar position after the use of each technique for the determination of CR. The calibration was performed to the maximal intercuspal position (MIP) for each volunteer. The investigated techniques were (A) the gothic arch tracer, (B) the adduction field method, (C) Dawson's bimanual manipulation, (D) the patient placing the tongue tip on the palatal rugae, (E) the patient placing the tongue tip to the border of the hard and soft palate, (F) the patient actively pulling the chin backwards, and (G) the examiner pushing the patient's chin back.

**Results** The position of the mandibular condyle was illustrated in a three-dimensional coordinate system, where the origin represented the MIP. Among the seven methods examined, five showed significant deviations compared to the MIP. Among these, two methods resulted in posterior deviation of the condyles. Methods C and E coincided with the MIP in all directions.

**Conclusions** Within the limitations of our study, we found that the smallest deviations from our theoretical zero (MIP) among the investigated centric relation determining methods were obtained with the bimanual mandibular manipulation technique derived from Dawson and the placement of the tongue tip on the border of the hard and soft palate (linguomandibular homotrophy theory).

**Keywords** Centric relation, Gothic arch tracing, Dawson's method, Digital motion analysis

\*Correspondence:

Bálint Jász

jasz.balint@semmelweis.hu

Full list of author information is available at the end of the article



© The Author(s) 2024. **Open Access** This article is licensed under a Creative Commons Attribution 4.0 International License, which permits use, sharing, adaptation, distribution and reproduction in any medium or format, as long as you give appropriate credit to the original author(s) and the source, provide a link to the Creative Commons licence, and indicate if changes were made. The images or other third party material in this article are included in the article's Creative Commons licence, unless indicated otherwise in a credit line to the material. If material is not included in the article's Creative Commons licence and your intended use is not permitted by statutory regulation or exceeds the permitted use, you will need to obtain permission directly from the copyright holder. To view a copy of this licence, visit <http://creativecommons.org/licenses/by/4.0/>. The Creative Commons Public Domain Dedication waiver (<http://creativecommons.org/publicdomain/zero/1.0/>) applies to the data made available in this article, unless otherwise stated in a credit line to the data.

## Background

The term centric relation (CR), which describes the relationship between the mandibular condyle and the articular fossa, has undergone significant changes in recent decades. While the first to fourth editions (1977) of the Glossary of Prosthodontic Terms (GPT) defined the most posterior position of the condyle as the CR, from the fifth edition (1987) to the latest ninth edition (2017), the anterior-superior position has been indicated as the centric position [1–4]. This repeatable maxillomandibular relationship is used in various fields of dentistry, including extensive prosthodontic rehabilitation, temporomandibular disorders (TMD) and orthodontic treatment [5–7]. As a result, numerous methods for determining the CR position of the mandible have been developed since the 1950s [8]. Several comparative studies have been conducted to determine the most appropriate technique [9–11]. Not only the definition but also the role of CR has changed and continues to change. In recent years, in addition to the CR, the importance of the MIP has become increasingly prominent, as has the need to maintain the original jaw relationship for as long as possible [7, 12].

Some studies have focused on the reproducibility of the methods, while others have focused on their accuracy. Accuracy was defined as the determination of the location of the condyle as close as possible to the current CR position. The majority of these studies use orthopantomograms, cone beam computed tomography (CBCT) or magnetic resonance imaging (MRI) examinations of the temporomandibular joint or traditional (average value) articulators [9, 13–16]. By involving digital technology, new opportunities for the comparative analysis of techniques for reproducing the CR position have opened up. In our study, we used a digital mandibular motion analyser (KaVo Arcus Digma 2). A recent review revealed ultrasound motion analyser devices to be sufficiently accurate. The device used in this study is one of these instruments [17].

In comparative studies of procedures for determining the CR position, there should be a distinction between studies performed on edentulous patients and patients with a stable maximum intercuspal position (MIP) [7, 12]. Patients with a stable MIP were recruited for this study. The study aimed to determine the extent to which the condylar positions obtained through different methods deviated from the MIP along the three axes. The null hypothesis was that none of the condyle positions determined by the different methods are different from the reference position.

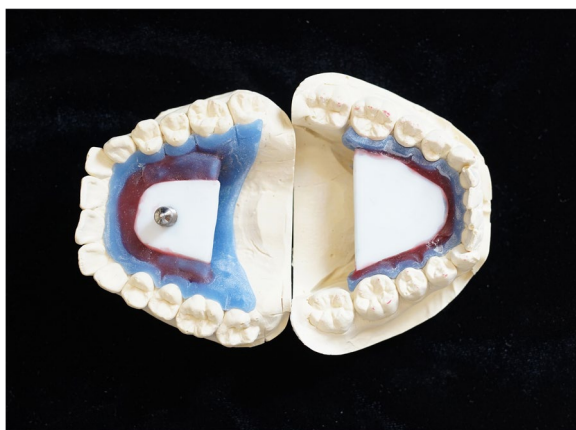## Methods

The study was conducted at the Department of Prosthodontics of Semmelweis University (Budapest, Hungary). Ethical approval was granted by the Semmelweis University Regional and Institutional Committee of Science and Research Ethics (No. 92/2013). The study was performed between 2014 and 2018. There were 34 volunteers who participated in the study, including 24 females and 10 males. The study group was selected from the staff and students of the Faculty of Dentistry of Semmelweis University. The mean (SD) age of the participants was 29.1 ( $\pm$  7.3) years.

Before conducting the measurements, general and dental anamneses were taken. The selection criteria for the study were as follows: (1) general good health and absence of dental and jaw developmental disorders; (2) preserved or restored dentition (excluding wisdom teeth); (3) in patients with restored dentition, the occluding surfaces of the restoration are not guiding surfaces in the articulatory movements; (4) no previous orthodontic treatment; (5) no medical history of temporomandibular disorders (TMD) and no complaints of TMD at the time of the examination; and (6) no occurrence of bruxism or other parafunctions and no abnormal tooth guidance (e.g., hyperbalanced contacts) based on the patient's history and dental examination. Dental status examination was performed together with patient examination according to the DC-TMD protocol to identify eventual temporomandibular joint (TMJ) and muscle-related complaints. The chewing system was assessed by an examiner (MD, DMD) who is experienced in DC-TMD examination and has worked in the field of gnathology for twenty years.

In the first session, putty-wash impressions of the lower and upper jaws were taken (Zetaplus, Oranwash, Zhermack, Badia Polesine, Italy). The impressions were poured with type IV die stone (Fuji Rock, GC International AG, Luzern, Switzerland) in the dental laboratory. From the completed casts, an intraoral gothic arch tracer was produced (Fig. 1). The pin was positioned on the upper jaw, while the tracing table was positioned on the lower jaw. The tracing table was placed parallel to the occlusal plane.

In the second session, the measurements were performed by the same examiner each time. The examinations were conducted using a KaVo Arcus Digma 2 digital motion analyser (KaVo GmbH, Biberach, Germany). In the initial step, a paraocclusal clutch was fixed on the vestibular surface of the mandibular teeth using a cold polymerizing composite resin material (Structure 2 SC, Voco GmbH, Cuxhaven, Germany). The ultrasound transmitter was attached to the clutch with magnets. Subsequently, the facebow was positioned using the left



**Fig. 1** Gothic arch tracer

infraorbital point as a reference, so the reference plane for the examination was the Frankfort horizontal plane. Before starting the digital analysis, an arbitrary axis calibration was performed: the position of the mandible transmitter was adjusted to the Frankfort horizontal plane with a calibration pin of known length. To determine the intercondylar axis, the lateral poles of the condyles were zeroed as well.

During the examination, the electronic position analysis (EPA) module was used, and calibration was performed to the maximum intercuspal position (MIP) of the mandible. The examiner determined the CR using seven different methods and registered the position of the mandible relative to the maxilla, along with the corresponding condylar position, after each determination.

The following CR determination techniques were investigated: (A) a gothic arch tracer, (B) the adduction field method [18] (in both methods, registration was performed at a slightly open position (at an elevated occlusal vertical dimension) due to the characteristics of the gothic arch tracer; the smallest possible increase was achieved with this intraoral drawing device), (C) Dawson's bimanual manipulation [19], (D) having the patient place the tip of the tongue on the palate in the area of the palatal rugae and close their mouth until the first contact of teeth occurred [20], (E) having the patient withdraw the tip of the tongue back to the border of the hard and soft palate and close their mouth until the first contact of teeth occurred (methods (D) and (E) are based on the theory of linguomandibular homotrophy) [20], (F) having the patient close the jaw until the first contact of teeth occurred while actively retruding the chin, and (G) the examiner pushing the patient's chin back during closing with a force of 20 N and fixing the final position to ensure that the condyle was not in a forced posterior position during the previous part of the examination [21]. All of

the examinations were performed by the same examiner, who graduated with MD and DMD degrees and worked in the field of gnathology for twenty years. Two randomly selected patients were re-examined. The second measurements were duplicates and were not included in the final statistical analysis. The weighted kappa coefficients for intraexaminer reliability ranged from 0.88 to 0.93.

Condylar positions corresponding to each determined jaw relationship were exported by using the manufacturer's program (KaVo KiD, KaVo GmbH, Biberach, Germany). Each condylar position was displayed in a three-dimensional coordinate system, where the origin was set as the initially calibrated MIP. On the sagittal x-axis, a positive value indicated a forwards/anterior position from the MIP, and a negative value indicated a more posterior/backwards position. Along the vertical y-axis, a positive value indicated a more cranial position than the MIP, while a negative value represented a more caudal position. For the horizontal z-axis, a positive deflection represented a deviation to the left, while a negative deflection represented a deviation to the right. Statistical differences were evaluated through the computation of the mean and 95% confidence interval (CI), signifying that upon replicating our measurements using identical sample sizes and methodologies, the mean outcomes would fall within the indicated interval with a probability of 95% (corresponding to a significance level of 0.05). Exported data were processed using GraphPad Prism software (GraphPad Software, Boston, USA) for statistical analysis.

## Results

After the EPA examination, the positions of both the right and left condyles were represented in a three-dimensional coordinate system. Therefore, for each determination method, one point was marked in the coordinate system for each condyle. The data were evaluated along the axes of the coordinate system. The deviations from the origin (MIP) were indicated along the x-, y- and z-axes for each method with a 95% confidence interval. Along the transverse z-axis, the deviation between the individual positions was 0 mm, with a 95% CI [-0.03, 0.03]. Thus, these values can be considered negligible in the study. Therefore, the distance between the MIP and the measuring point was calculated as a common vector between the x-axis and y-axis (Fig. 2).

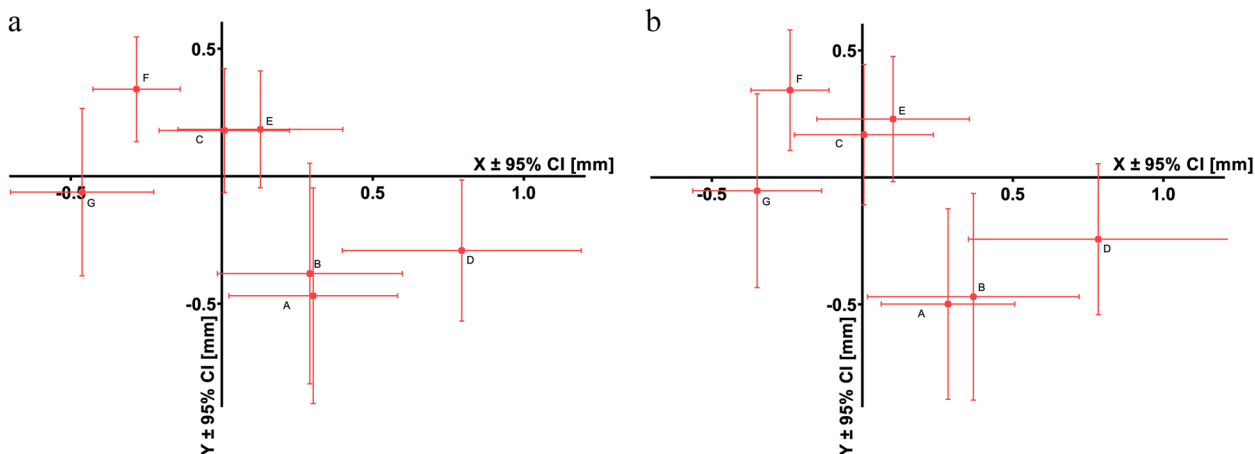
On the x-axis, the positions determined by the Dawson technique (C) and by placing the tongue on the border of the hard and soft palate (E) on both sides and the adduction field method (B) on the left side did not differ significantly from those of the MIP. However, there was a significant difference between the MIP and the positions determined by the apex of the gothic arch tracer (A), by

**Table 1** Raw deviations (averages and 95% confidence intervals) from the MIP on the x (sagittal) and y (vertical) axes for different CR determination techniques on the right side. Significant differences from the MIP (i.e., sagittal=0, vertical=0) are marked with italics and asterisks

	Sagittal	Vertical
Apex of the gothic arch tracer (A)	<i>0.28 mm, 95% CI [0.06, 0.51]*</i>	<i>-0.5 mm, 95% CI [-0.87, -0.12]*</i>
Adduction field (B)	<i>0.37 mm, 95% CI [0.02, 0.72]*</i>	<i>-0.47 mm, 95% CI [-0.88, -0.06]*</i>
Dawson technique (C)	0 mm, 95% CI [-0.23, 0.23]	0.17 mm, 95% CI [-0.11, 0.45]
Tongue at the palatal rugae (D)	<i>0.78 mm, 95% CI [0.35, 1.22]*</i>	-0.24 mm, 95% CI [-0.54, 0.05]
Tongue at the hard-soft palate border (E)	0.1 mm, 95% CI [-0.15, 0.36]	0.23 mm, 95% CI [-0.02, 0.48]
Active retrusion (F)	<i>-0.24 mm, 95% CI [-0.37, -0.11]*</i>	<i>0.34 mm, 95% CI [0.11, 0.58]*</i>
Passive retrusion (G)	<i>-0.35 mm, 95% CI [-0.56, 0.14]*</i>	-0.05 mm, 95% CI [-0.43, 0.33]

**Table 2** Raw deviations (averages and 95% confidence intervals) from the MIP on the x (sagittal) and y (vertical) axes for different CR determination techniques on the left side. Significant differences from the MIP (i.e., sagittal=0, vertical=0) are marked with italics and asterisks

	Sagittal	Vertical
Apex of the gothic arch tracer (A)	<i>0.3 mm, 95% CI [0.02, 0.58]*</i>	<i>-0.47 mm, 95% CI [-0.89, -0.05]*</i>
Adduction field (B)	0.29 mm, 95% CI [-0.01, 0.6]	-0.38 mm, 95% CI [-0.81, 0.05]
Dawson technique (C)	0.01 mm, 95% CI [-0.21, 0.22]	0.18 mm, 95% CI [-0.06, 0.42]
Tongue at the palatal rugae (D)	<i>0.79 mm, 95% CI [0.4, 1.19]*</i>	<i>-0.29 mm, 95% CI [-0.57, -0.01]*</i>
Tongue at the hard-soft palate border (E)	0.13 mm, 95% CI [-0.15, 0.4]	0.18 mm, 95% CI [-0.05, 0.41]
Active retrusion (F)	<i>-0.28 mm, 95% CI [-0.43, -0.14]*</i>	<i>0.34 mm, 95% CI [0.14, 0.55]*</i>
Passive retrusion (G)	<i>-0.46 mm, 95% CI [-0.7, -0.23]*</i>	-0.06 mm, 95% CI [-0.39, 0.27]



**Fig. 2** Deviations of the condyle from the MIP (origin) after different CR determination techniques on the left (a) and right (b) sides: apex of the gothic arch tracer (A), adduction field (B), Dawson technique (C), tongue at the palatal rugae (D), tongue at the hard-soft palate border (E), active retrusion (F), and passive retrusion (G)

placing the tongue on the palatal rugae (D), and by the active and passive retrusion of the chin (F and G) on both sides and by the adduction field method (B) on the right side.

On the y-axis, the positions determined by the Dawson manipulation (C), placing the tongue to the border of the hard and soft palate (E), and mandibular retrusion

by the operator (G) did not significantly differ from the MIP (y=0) on either side. The positions determined by placing the tongue to the rugae (D) on the right side and by the adduction field method (B) on the left side also did not significantly differ from the MIP. However, there was a significant difference from the MIP in the positions determined by the apex of the gothic arch tracer

(A) and by patient retrusion of the mandible (F) on both sides. Placing the tongue to the rugae (D) on the left side and the adduction field method (B) on the right side also yielded significant differences from the MIP (Tables 1 and 2).

## Discussion

The centric relation of the mandible is still a controversial topic. Some authors consider a discrepancy between the CR and the MIP (centric slide) to be a predisposing factor for TMD [22, 23]. Considering the very frequent prevalence of centric slides, others do not consider it a pathological condition and thus do not consider the role of CR to be central [7, 12]. These authors argue that, in principle, the MIP is the ideal position, independent of the condylar position. Achieving the CR position is only required in cases of restorations for partially or completely edentulous patients, full-mouth rehabilitation, and orthodontic and orthognathic treatments involving the whole jaw [12]. However, numerous studies have compared different CR determination methods to each other or to a preferred position (mostly the MIP) [9, 24–28]. In most cases, dentate patients formed the study group, but in some cases, edentulous patients were also involved [9, 26, 29]. The main differences among these studies are in the examination procedures used. The oldest and most widely used method is to mount the casts in an articulator after determining the CR position by each method and then compare them [16, 24, 25]. The advantages of this method are its simplicity and relatively low cost, but its limitations are the inaccuracy of mounting the casts and the millimetre scale used for measurement. In some studies, different imaging technologies have been used to examine the different positions [13, 14, 21]. With these methods, accurate images of the condyle-fossa relationship can be obtained, but this technique is relatively expensive, and when using CBCT, radiation exposure is not negligible.

In addition to these previous studies, the use of digital technology represents a new methodology. Axiography is an examination method that has been used for almost 100 years to assess the position and movements of the lower jaw relative to a reference plane. Axiography has improved with the use of digital technology and digital motion analysis [30]. In our study, we used an Arcus Digma 2, a digital motion analyser that operates with ultrasound. The device includes four ultrasonic transmitters attached to the lower jaw and eight ultrasonic receivers connected to the upper jaw through an arch. An extremely high accuracy of 50 micrometres can be achieved with this device [31].

Our study is the most comprehensive comparison to date, examining the accuracy of seven different

techniques commonly used to determine centric relation (CR) in everyday practice. Among the seven techniques, five showed significant differences along at least one axis compared to the most reproducible and widely accepted reference point, which was the MIP [9, 12]. Neither the Dawson technique nor placing the tongue to the border of the hard and soft palate showed significant differences from the reference point along the three axes. Positioning the tongue at the palatal rugae, although not significantly different along the y-axis, exhibited the largest deviation along the x-axis, suggesting that the use of this method could result in capturing the mandible in a more protrusive position than desired. Mandibular retrusion by the patient, as well as backwards pressure on the chin, clearly resulted in a retrusive position of the lower jaw, which, despite being highly reproducible according to the literature, carries the risk of capturing the jaw in a posterior condylar position. The results obtained from a gothic arch tracer (the apex of the arrow and the adduction field) significantly differed from the reference point along at least one axis. This may be due to the translational movement of the condyle, which occurs even with minimal opening, resulting in a significantly anterior and downwards condylar position measurement. Accordingly, dentists need to consider and accept certain inaccuracies when using this method in patients without tooth loss.

A systematic review was published in 2021, in which a search was conducted on the MEDLINE, PubMed, Cochrane, and Google Scholar databases using the terms ‘Centric relation techniques’ AND/OR ‘Retruded mandibular position’ for the period between 1998 and 2019. Out of 958 articles, only 9 met the criteria defined for the study. Among these, five studies included edentulous participants, while four examined individuals with complete dentition. Based on these latter articles, the review concluded that the Dawson technique was the most accurate overall for the determination of CR in dentate patients [32]. This finding is consistent with the results of the present study.

## Conclusion

According to this study, we can conclude that when comparing different methods used to determine the CR in patients with stable MIPs, the smallest deviation from the reference position was found with the bimanual mandibular manipulation technique derived from Dawson. The second smallest deviation was observed when the tongue tip was placed on the border of the hard and soft palate according to the linguomandibular homotrophy theory. Among the seven methods examined, five showed significant deviations compared to the MIP on at least one axis, but the magnitude of these differences was within

+/- 1 mm. Therefore, methods that do not result in posterior deviation (apex of the gothic arch tracer, adduction field, Dawson technique, tongue at the palatal rugae, tongue at the hard-soft palate border) are likely to be applicable in clinical practice. Active and passive retrusion of the mandible both resulted in a more posterior position compared to the MIP, which was calibrated at the beginning of the examination.

**Abbreviations**

CR	Centric relation
CBCT	Cone beam computed tomography
CI	Confidence interval
EPA	Electronic position analysis
GPT	Glossary of Prosthodontic Terms
MRI	Magnetic resonance imaging
MIP	Maximal intercuspal position
TMD	Temporomandibular disorders
TMJ	Temporomandibular joint

**Informed consent**

Patients included in this study received both verbal and written information about the study before the examination, and an informed consent form was signed by all participants. The confidentiality of the data was confirmed

**Authors' contributions**

All seven authors contributed to the study's conception and design. Material preparation: MJ, BJ, SzA, PS, SzK, PH. Data collection: MJ, BJ. Data analysis, interpretation: BJ, PS, SzA. Statistical analysis: TG. Report supervision: MJ, SzK. The first draft of the manuscript: BJ. Comments on previous versions of the manuscript: PH, MJ, SzA, PS, SzK. All even authors read and approved the final manuscript.

**Funding**

Open access funding provided by Semmelweis University. This study was not funded by any institution or company.

**Availability of data and materials**

The datasets used and/or analysed during the current study are available from the corresponding author upon reasonable request.

**Declarations**

**Ethics approval and consent to participate**

All procedures in this study were performed in accordance with the ethical standards of the institutional research committee of Semmelweis University (Ref No: ETT-TUKEB 92/2013) and with the 1964 Helsinki Declaration and its later amendments or comparable ethical standards.

**Consent for publication**

Not applicable.

**Competing interests**

The authors declare no competing interests.

**Author details**

<sup>1</sup>Department of Prosthodontics, Faculty of Dentistry, Semmelweis University, Szentkirályi u. 47, Budapest 1088, Hungary. <sup>2</sup>Faculty of Information Technology and Bionics, Pázmány Péter Catholic University, Budapest, Hungary. <sup>3</sup>Division of Oncology, Department of Internal Medicine and Oncology, Faculty of Medicine, Semmelweis University, Budapest, Hungary.

Received: 19 September 2023 Accepted: 11 March 2024

Published online: 18 March 2024

**References**

1. The Glossary of Prosthodontic Terms: Ninth Edition. *J Prosthet Dent.* 2017;117(5s):e1-e105.
2. Glossary of prosthodontic terms. *J Prosthet Dent.* 1987;58(6):713-62.
3. The Nomenclature Committee Academy of Denture P, Aidsman IK. Glossary of prosthodontic terms. *J Prosthet Dent.* 1977;38(1):66-109.
4. Wiens JP, Goldstein GR, Andrawis M, Choi M, Priebe JW. Defining centric relation. *J Prosthet Dent.* 2018;120(1):114-22.
5. Dawson PE. A classification system for occlusions that relates maximal intercuspation to the position and condition of the temporomandibular joints. *J Prosthet Dent.* 1996;75(1):60-6.
6. Goldstein G, Andrawis M, Choi M, Wiens J, Janal MN. A survey to determine agreement regarding the definition of centric relation. *J Prosthet Dent.* 2017;117(3):426-9.
7. Kattadiyil MT, Alzaid AA, Campbell SD. The Relationship Between Centric Occlusion and The Maximal Intercuspal Position and Their Use as Treatment Positions for Complete Mouth Rehabilitation: Best Evidence Consensus Statement. *J Prosthodont.* 2021;30(51):26-33.
8. Harris E. Centric relation of the mandible. *J Am Dent Assoc.* 1948;37(5):565-72.
9. Keshvad A, Winstanley RB. Comparison of the replicability of routinely used centric relation registration techniques. *J Prosthodont.* 2003;12(2):90-101.
10. Zonnenberg AJ, Mulder J. Reproducibility of 2 methods to locate centric relation in healthy individuals and TMD patients. *Eur J Prosthodont Restor Dent.* 2012;20(4):151-8.
11. McKee JR. Comparing condylar position repeatability for standardized versus nonstandardized methods of achieving centric relation. *J Prosthet Dent.* 1997;77(3):280-4.
12. Zonnenberg AJ, Türp JC, Greene CS. Centric relation critically revisited-What are the clinical implications? *J Oral Rehabil.* 2021;48(9):1050-5.
13. Ismail YH, Rokni A. Radiographic study of condylar position in centric relation and centric occlusion. *J Prosthet Dent.* 1980;43(3):327-30.
14. Ferreira Ade F, Henriques JC, Almeida GA, Machado AR, Machado NA, Fernandes Neto AJ. Comparative analysis between mandibular positions in centric relation and maximum intercuspation by cone beam computed tomography (CONE-BEAM). *J Appl Oral Sci.* 2009;17 Suppl(spe):27-34.
15. Kandasamy S, Greene CS, Obrez A. An evidence-based evaluation of the concept of centric relation in the 21st century. *Quintessence Int.* 2018;49(9):755-60.
16. McKee JR. Comparing condylar positions achieved through bimanual manipulation to condylar positions achieved through masticatory muscle contraction against an anterior deprogrammer: a pilot study. *J Prosthet Dent.* 2005;94(4):389-93.
17. Woodford SC, Robinson DL, Mehl A, Lee PVS, Ackland DC. Measurement of normal and pathological mandibular and temporomandibular joint kinematics: A systematic review. *J Biomechanics.* 2020;111:109994.
18. Aprile H, Saizar P. Gothic arch tracing and temporomandibular anatomy. *J Am Dent Assoc.* 1947;35(4):256-61.
19. Dawson PE. Temporomandibular joint pain-dysfunction problems can be solved. *J Prosthet Dent.* 1973;29(1):100-12.
20. Wild W. Funktionelle Prothetik. Basel: Benno Schwabe & Co. Verlag; 1950. 202 p.
21. Kandasamy S, Boeddinghaus R, Kruger E. Condylar position assessed by magnetic resonance imaging after various bite position registrations. *Am J Orthod Dentofacial Orthop.* 2013;144(4):512-7.
22. Cordray FE. Articulated dental cast analysis of asymptomatic and symptomatic populations. *Int J Oral Sci.* 2016;8(2):126-32.
23. Padala S, Padmanabhan S, Chithranjan AB. Comparative evaluation of condylar position in symptomatic (TMJ dysfunction) and asymptomatic individuals. *Indian J Dent Res.* 2012;23(1):122.
24. Utz KH, Lückereath W, Schwarting P, Noethlich W, Büttner R, Grüner M, et al. Is there "a best" centric relation record? Centric relation records, condyle positions, and their practical significance. *Int J Prosthodont.* 2022;36(3):262-72.
25. Kantor ME, Silverman SI, Garfinkel L. Centric-relation recording techniques--a comparative investigation. *J Prosthet Dent.* 1972;28(6):593-600.
26. de Sousa Erolvino IC, Goiato MC, de Moraes Melo Neto CL, de Caxias FP, da Silva EVF, Túrcio KHL, et al. Clinical reproducibility of different centric relation recording techniques in edentulous individuals: An observational cross-sectional study. *J Prosthodont.* 2023;32(6):497-504.

27. Lucia VO. A technique for recording centric relation. *J Prosthetic Dentistry*. 1964;14(3):492–505.
28. Long JH Jr. Location of the terminal hinge axis by intraoral means. *J Prosthet Dent*. 1970;23(1):11–24.
29. Shanahan TE. Physiologic jaw relations and occlusion of complete dentures. 1955. *J Prosthet Dent*. 2004;91(3):203–5.
30. Starcke EN. The history of articulators: from facebows to the gnathograph, a brief history of early devices developed for recording condylar movement: part II. *J Prosthodont*. 2002;11(1):53–62.
31. KaVo Dental. Arcus Digma Instructions for Use 2008 [Available from: [https://kavo.widen.net/content/5f6sxpsek/original/GA\\_ARCUS\\_digmall\\_20080619\\_01\\_en.pdf?u=ai5cab&download=true](https://kavo.widen.net/content/5f6sxpsek/original/GA_ARCUS_digmall_20080619_01_en.pdf?u=ai5cab&download=true). Accessed 14 Sept 2023.
32. Ramaswamy S, Kore AR, Sanyal PK, Joshi A, Hathiwala S, Tayade PN. Techniques to Guide the Mandible to Centric Relation-A Systematic Review. *J Clin Diagnostic Res*. 2021;15(7):1–7.

### **Publisher's Note**

Springer Nature remains neutral with regard to jurisdictional claims in published maps and institutional affiliations.